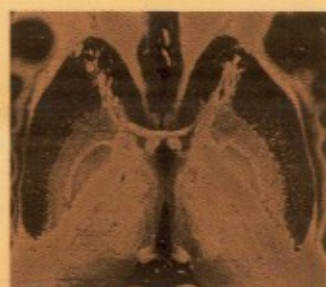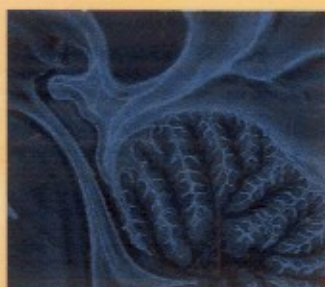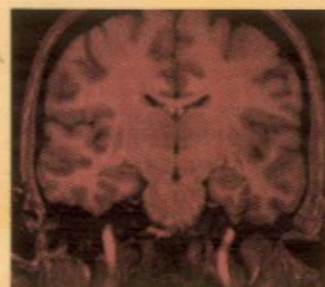


third edition

# Neuroanatomy



text and atlas

John H. Martin

INTERNATIONAL EDITION

# Contents

Preface	xix
Acknowledgments	xxi
Guide to Using This Book	xxiii

## ***1 The Central Nervous System*** 1

### **1** Introduction to the Central Nervous System 3

Neurons and Glia Are the Two Principal Cellular Constituents of the Nervous System 4

The Nervous System Consists of Separate Peripheral and Central Components 6

The Spinal Cord Displays the Simplest Organization of All Seven Major Divisions 8

The Brain Stem and Cerebellum Regulate Body Functions and Movements 8

The Diencephalon Consists of the Thalamus and Hypothalamus 11

The Cerebral Hemispheres Have the Most Complex Three-Dimensional Configuration of All Central Nervous System Divisions 11

Cavities Within the Central Nervous System Contain Cerebrospinal Fluid 18

The Central Nervous System Is Covered by Three Meningeal Layers 19

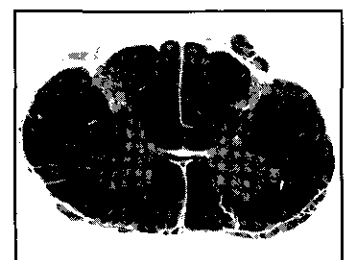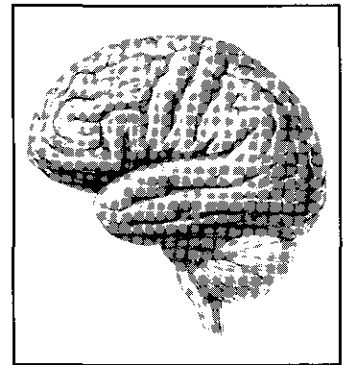
An Introduction to Neuroanatomical Terms 21

**Summary** 25

### **2** Structural and Functional Organization of the Central Nervous System 27

The Dorsal Column—Medial Lemniscal System and Corticospinal Tract Have a Component at Each Level of the Neuraxis 28

The Modulatory Systems of the Brain Have Diffuse Connections and Use Different Neurotransmitters 29



Guidelines for Studying the Regional Anatomy and Interconnections of the Central Nervous System 32

The Spinal Cord Has a Central Cellular Region Surrounded by a Region That Contains Myelinated Axons 32

Surface Features of the Brain Stem Mark Key Internal Structures 34

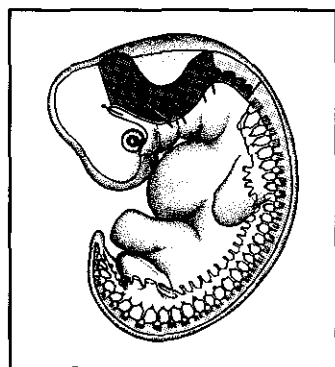
The Internal Capsule Contains Ascending and Descending Axons 41

Cerebral Cortex Neurons Are Organized Into Layers 42

The Cerebral Cortex Has an Input-Output Organization 43

The Cytoarchitectonic Map of the Cerebral Cortex Is the Basis for a Map of Cortical Function 44

**Summary 52**



### 3 Development of the Central Nervous System 55

The Neurons and Glial Cells Derive From Cells of the Neural Plate 55

The Neural Tube Forms Five Brain Vesicles and the Spinal Cord 57

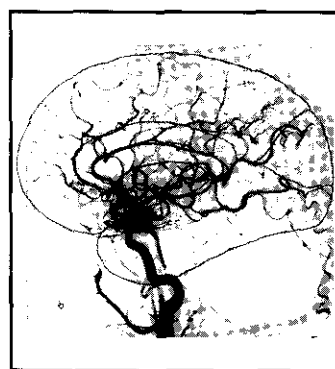
The Spinal Cord and Brain Stem Have a Segmented Structure 59

The Location of Developing Spinal Cord and Brain Stem Nuclei Determine Their Functions and Connections 63

The Cerebellum Develops From the Rhombic Lips 69

The Rostral Portion of the Neural Tube Gives Rise to the Diencephalon and Cerebral Hemispheres 69

**Summary 78**



### 4 Vasculature of the Central Nervous System and the Cerebrospinal Fluid 81

Neural Tissue Depends on Continuous Arterial Blood Supply 82

The Vertebral and Carotid Arteries Supply Blood to the Central Nervous System 83

The Spinal and Radicular Arteries Supply Blood to the Spinal Cord 85

The Vertebral and Basilar Arteries Supply Blood to the Brain Stem 86

The Internal Carotid Artery Has Four Principal Portions 86

The Anterior and Posterior Circulations Supply the Diencephalon and Cerebral Hemispheres 86

Cerebral Veins Drain Into the Dural Sinuses 92

The Blood-Brain Barrier Isolates the Chemical Environment of the Central Nervous System From That of the Rest of the Body 96

Cerebrospinal Fluid Serves Many Diverse Functions 97

**Summary 102**

## II Sensory Systems 105

### 5 Spinal Somatic Sensory Systems 107

#### Functional Anatomy of the Spinal Somatic Sensory Pathways 107

The Dorsal Column—Medial Lemniscal System and the Anterolateral System Mediate Different Somatic Sensations 108

The Two Ascending Somatic Sensory Pathways Each Receive Inputs From Different Classes of Sensory Receptor Neurons 109

The Somatic Sensory Pathways Have Different Relay Nuclei in the Spinal Cord and Brain Stem 109

The Two Ascending Somatic Sensory Pathways Decussate at Different Levels of the Neuraxis 109

The Dorsal Column—Medial Lemniscal and Anterolateral Systems Synapse in Different Brain Stem, Diencephalic, and Cortical Regions 109

#### Regional Anatomy of the Spinal Somatic Sensory Pathways 111

The Peripheral Axon Terminals of Dorsal Root Ganglion Neurons Contain the Somatic Sensory Receptor 114

Dorsal Root Axons With Different Diameters Terminate in Different Central Nervous System Locations 117

The Dorsal Columns Contain Ascending Branches of Mechanoreceptive Sensory Fibers 119

The Somatotopic Organization of the Dorsal Columns Is Revealed in Human Postmortem Specimens 119

The Decussation of the Dorsal Column—Medial Lemniscal System Is in the Caudal Medulla 120

Vascular Lesions of the Medulla Differentially Affect Somatic Sensory Function 124

Descending Pain Suppression Pathways Originate From the Brain Stem 124

Three Separate Nuclei in the Thalamus Process Somatic Sensory Information 125

Several Areas of the Parietal Lobe Process Touch and Proprioceptive Information 126

Limbic and Insular Areas Contain the Cortical Representations of Pain, Itch, and Temperature Sensations 130

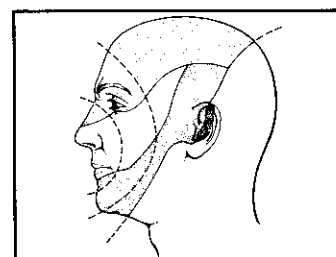
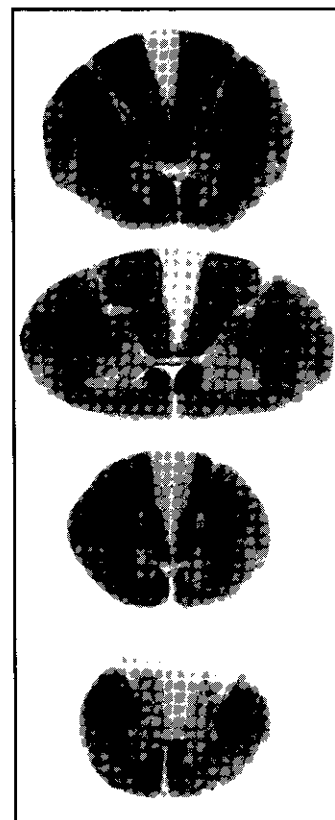
**Summary 131**

### 6 Cranial Nerves and the Trigeminal and Viscerosensory Systems 135


#### Cranial Nerves and Nuclei 135

Important Differences Exist Between the Sensory and Motor Innervation of Cranial Structures and That of the Limbs and Trunk 137

There Are Seven Functional Categories of Cranial Nerves 137



Cranial Nerve Nuclei Are Organized Into Rostrocaudal Columns	140
<b>Functional Anatomy of the Trigeminal and Viscerosensory Systems</b>	<b>140</b>
Separate Trigeminal Pathways Mediate Touch and Pain and Temperature Senses	143
The Viscerosensory System Originates from the Caudal Solitary Nucleus	145
<b>Regional Anatomy of the Trigeminal and Viscerosensory Systems</b>	<b>145</b>
Separate Sensory Roots Innervate Different Parts of the Face and Mucous Membranes of the Head	145
The Key Components of the Trigeminal System Are Present at All Levels of the Brain Stem	146
The Caudal Solitary and Parabrachial Nuclei Are Key Brain Stem Viscerosensory Integrative Centers	155
The Ventral Posterior Nucleus Contains Separate Trigeminal and Spinal Subdivisions and Projects to the Postcentral Gyrus	155
The Thalamic Viscerosensory Relay Nucleus Projects to the Insular Cortex	157
<b>Summary</b>	<b>158</b>



## 7 The Visual System 161

### **Functional Anatomy of the Visual System 161**

Anatomically Separate Visual Pathways Mediate Perception and Ocular Reflex Function 161

The Pathway to the Primary Visual Cortex Is Important for Perception of the Form, Color, and Motion of Visual Stimuli 162

The Pathway to the Midbrain Is Important in Voluntary and Reflexive Control of the Eyes 162

### **Regional Anatomy of the Visual System 162**

Optical Properties of the Eye Transform Visual Stimuli 162

The Retina Contains Five Major Layers 165

Each Optic Nerve Contains All of the Axons of Ganglion Cells in the Ipsilateral Retina 169

The Superior Colliculus Is Important in Oculomotor Control and Orientation 169

The Retinotopic Maps in Each Layer of the Lateral Geniculate Nucleus Are Aligned 171

The Primary Visual Cortex Is the Target of Projections From the Lateral Geniculate Nucleus 173

The Magnocellular and Parvocellular Systems Have Differential Laminar Projections in the Primary Visual Cortex 173

The Primary Visual Cortex Has a Columnar Organization 176

Higher-Order Visual Cortical Areas Analyze Distinct Aspects of Visual Stimuli 180

The Visual Field Changes in Characteristic Ways After Damage to the Visual System 184

Summary 187

## 8 The Auditory System 191

**Functional Anatomy of the Auditory System** 192

Parallel Ascending Auditory Pathways May Be Involved in Different Aspects of Hearing 192

**Regional Anatomy of the Auditory System** 194

The Auditory Sensory Organs Are Located Within the Membranous Labyrinth 194

The Topography of Connections Between Brain Stem Auditory Nuclei Provides Insight Into the Functions of Parallel Ascending Auditory Pathways 196

The Olivocochlear System May Regulate Hair Cell Sensitivity 198

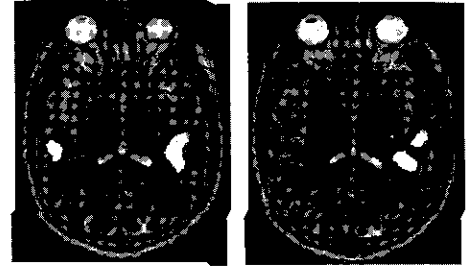
*Auditory Brain Stem Axons Ascend in the Lateral Lemniscus* 199

The Inferior Colliculus Is Located in the Midbrain Tectum 199

The Medial Geniculate Nucleus Contains a Division That Is Tonotopically Organized 200

The Auditory Cortical Areas Are Located on the Superior Surface of the Temporal Lobe 201

Summary 204



## 9 Chemical Senses: Taste and Smell 207

**The Gustatory System: Taste** 208

The Ascending Gustatory Pathway Projects to the Ipsilateral Insular Cortex 208

**Regional Anatomy of the Gustatory System** 210

Branches of the Facial, Glossopharyngeal, and Vagus Nerves Innervate Different Parts of the Oral Cavity 210

The Solitary Nucleus Is the First Central Nervous System Relay for Taste 211

The Parvocellular Portion of the Ventral Posterior Medial Nucleus Relays Gustatory Information to the Insular Cortex and Operculum 212

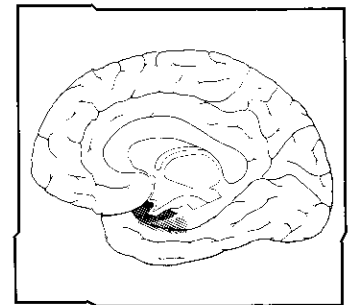
**The Olfactory System: Smell** 216

The Olfactory Projection to the Cerebral Cortex Does Not Relay in the Thalamus 216

**Regional Anatomy of the Olfactory System** 216

The Primary Olfactory Neurons Are Located in the Nasal Mucosa 216

The Olfactory Bulb Is the First Central Nervous System Relay for Olfactory Input 219



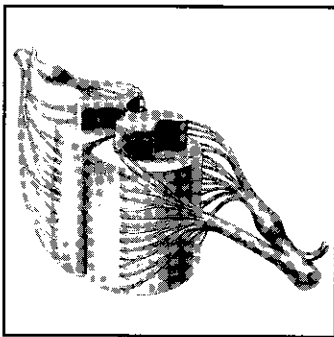
The Olfactory Bulb Projects to Structures on the Ventral Brain Surface Through the Olfactory Tract 219

The Primary Olfactory Cortex Receives a Direct Input From the Olfactory Bulb 219

Projections From the Olfactory Bulb to the Cortex Have a Parallel Organization 222

**Summary** 224

### **III Motor Systems 227**



## **10 Descending Motor Pathways and the Motor Function of the Spinal Cord 229**

**Functional Anatomy of the Motor Systems and the Descending Motor Pathways** 230

Diverse Central Nervous System Structures Comprise the Motor Systems 230

Many Cortical Regions Are Recruited Into Action During Visually Guided Movements 231

There Are Three Functional Classes of Descending Pathways 232

Multiple Parallel Motor Control Pathways Originate From the Cortex and Brain Stem 232

Motor Pathways of the Spinal Cord Have a Hierarchical Organization 232

The Functional Organization of the Descending Pathways Parallels the Somatotopic Organization of the Motor Nuclei in the Ventral Horn 234

**Regional Anatomy of the Motor Systems and the Descending Motor Pathways** 235

The Cortical Motor Areas Are Located in the Frontal Lobe 239

The Projection From Cortical Motor Regions Passes Through the Internal Capsule En Route to the Brain Stem and Spinal Cord 243

The Corticospinal Tract Courses in the Base of the Midbrain 247

Descending Cortical Fibers Separate Into Small Fascicles in the Ventral Pons 247

The Pontine and Medullary Reticular Formation Gives Rise to the Reticulospinal Tracts 247

The Lateral Corticospinal Tract Decussates in the Caudal Medulla 248

The Intermediate Zone and Ventral Horn of the Spinal Cord Receive Input From the Descending Pathways 248

Lesions of the Descending Cortical Pathway in the Brain and Spinal Cord Produce Flaccid Paralysis Followed by Spasticity 250

**Summary** 255

# 11 Cranial Nerve Motor Nuclei and Brain Stem Motor Functions 259

## Organization and Functional Anatomy of Cranial Motor Nuclei 260

There Are Three Columns of Cranial Nerve Motor Nuclei 260

The Cranial Motor Nuclei Are Controlled by the Cerebral Cortex and Diencephalon 260

Neurons in the Somatic Skeletal Motor Column Innervate the Tongue and Extraocular Muscles 260

The Branchiomeric Motor Column Innervates Skeletal Muscles That Develop From the Branchial Arches 263

The Autonomic Motor Column Contains Parasympathetic Preganglionic Neurons 266

## Regional Anatomy of Cranial Motor Nuclei 269

Lesion of the Genu of the Internal Capsule Interrupts the Corticobulbar Tract 269

Parasympathetic Neurons in the Midbrain Regulate Pupil Size 270

The Descending Cortical Fibers Break Up Into Small Fascicles in the Pons 273

The Trigeminal Motor Nucleus Is Medial to the Main Trigeminal Sensory Nucleus 273

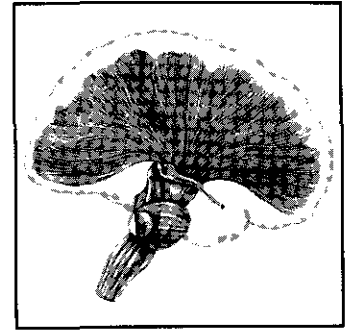
The Fibers of the Facial Nerve Have a Complex Trajectory Through the Pons 273

The Glossopharyngeal Nerve Enters and Exits From the Rostral Medulla 275

A Level Through the Midmedulla Reveals the Locations of Six Cranial Nerve Nuclei 276

The Spinal Accessory Nucleus Is Located at the Junction of the Spinal Cord and Medulla 277

Summary 278



# 12 The Vestibular and Oculomotor Systems 281

## Functional Anatomy of the Vestibular System 282

An Ascending Pathway From the Vestibular Nuclei to the Thalamus Is Important for Perception and Orientation 282

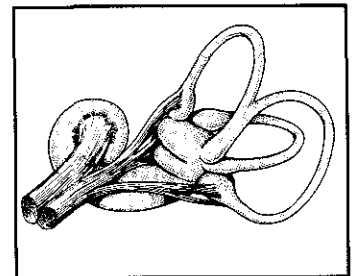
The Vestibular Nuclei Have Functionally Distinct Efferent Projections for Axial Muscle Control and Perception 283

## Functional Anatomy of the Oculomotor System and the Control of Gaze 283

The Extraocular Motor Neurons Are Located in Three Cranial Nerve Motor Nuclei 283

Voluntary Eye Movement Direction Is Controlled by Neurons in the Frontal Lobe and the Parietal-Temporal-Occipital Association Cortex 283

The Vestibuloocular Reflex Maintains Direction of Gaze During Head Movement 289





## **Regional Organization of the Vestibular and Oculomotor Systems 289**

Vestibular Nerve Fibers Project to the Vestibular Nuclei and the Cerebellum 289

The Vestibular Nuclei Have Functionally Diverse Projections 289

The Extraocular Motor Nuclei Are Located in the Pons and Midbrain 293

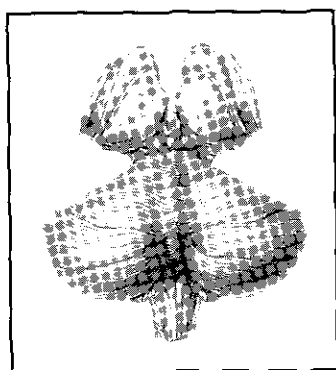
Rostral Midbrain Neurons Organize Vertical Saccades 295

Eye Movement Control Involves the Integrated Functions of Many Brain Stem Structures 296

The Ventral Posterior Nucleus of the Thalamus Transmits Vestibular Information to the Parietal and Insular Cortical Areas 298

Multiple Areas of the Cerebral Cortex Function in Eye Movement Control 298

**Summary 298**



## **13 The Cerebellum 301**

**Gross Anatomy of the Cerebellum 301**

**Functional Anatomy of the Cerebellum 304**

All Three Functional Divisions of the Cerebellum Display a Similar Input-Output Organization 304

**Regional Anatomy of the Cerebellum 311**

The Intrinsic Circuitry of the Cerebellar Cortex Is Similar for the Different Functional Divisions 312

Spinal Cord and Medullary Sections Reveal Nuclei and Paths Transmitting Somatic Sensory Information to the Cerebellum 315

The Inferior Olivary Nucleus Is the Only Source of Climbing Fibers 318

The Vestibulocerebellum Receives Input From Primary and Secondary Vestibular Neurons 318

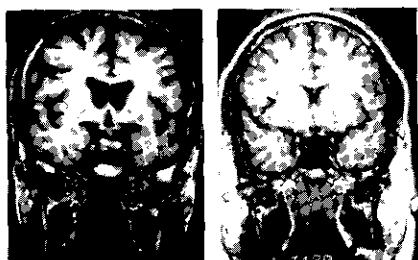
The Pontine Nuclei Provide the Major Input to the Cerebrocerebellum 318

The Deep Cerebellar Nuclei Are Located Within the White Matter 319

The Superior Cerebellar Peduncle Decussates in the Caudal Midbrain 319

The Ventrolateral Nucleus Relays Cerebellar Output to the Premotor and Primary Motor Cortical Areas 321

**Summary 324**



## **14 The Basal Ganglia 327**

**Functional Anatomy of the Basal Ganglia 328**

Separate Components of the Basal Ganglia Process Incoming Information and Mediate the Output 328

Parallel Circuits Course Through the Basal Ganglia 330

Knowledge of Basal Ganglia Connections and Neurotransmitters Provides Insight Into Their Function in Health and Disease 330

### **Regional Anatomy of the Basal Ganglia 334**

The Anterior Limb of the Internal Capsule Separates the Head of the Caudate Nucleus From the Putamen 334

Cell Bridges Link the Caudate Nucleus and the Putamen 338

The External Segment of the Globus Pallidus and the Ventral Pallidum Are Separated by the Anterior Commissure 341

The Ansa Lenticularis and the Lenticular Fasciculus Are Output Paths of the Internal Segment of the Globus Pallidus 342

Lesion of the Subthalamic Region Produces Hemiballism 343

The Substantia Nigra Contains Two Anatomical Divisions 343

The Vascular Supply of the Basal Ganglia Is Provided by the Middle Cerebral Artery 346

**Summary 347**

## **IV Integrative Systems 349**

### **15 The Hypothalamus and Regulation of Endocrine and Visceral Functions 351**

#### **Functional Anatomy of the Neuroendocrine Systems 353**

The Hypothalamus Is Divided Into Three Functionally Distinct Mediolateral Zones 353

Separate Parvocellular and Magnocellular Neurosecretory Systems Regulate Hormone Release From the Anterior and Posterior Lobes of the Pituitary 355

#### **Functional Anatomy of Autonomic Nervous System Control 358**

The Parasympathetic and Sympathetic Divisions of the Autonomic Nervous System Originate From Different Central Nervous System Locations 358

Hypothalamic Nuclei Coordinate Integrated Responses to Body and Environmental Stimuli via Local Circuits and Descending Visceral Motor Pathways 359

#### **Regional Anatomy of the Hypothalamus 363**

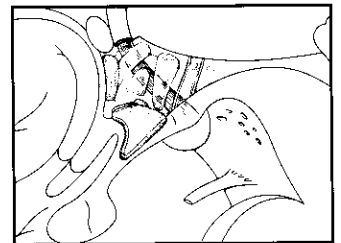
The Preoptic Area Influences Release of Reproductive Hormones From the Anterior Pituitary 363

The Supraoptic and Paraventricular Nuclei Comprise the Magnocellular Neurosecretory System 364

The Suprachiasmatic Nucleus Is the Master Clock for Circadian Rhythms 366

Parvocellular Neurosecretory Neurons Project to the Median Eminence 366

The Posterior Hypothalamus Contains the Mammillary Bodies 367



Neurons in the Lateral Hypothalamic Area Can Have Widespread Effects on Cortical Neuron Function 367

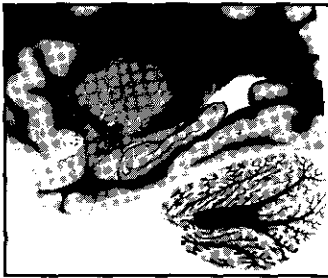Descending Autonomic Fibers Course in the Periaqueductal Gray Matter and in the Lateral Tegmentum 370

Nuclei in the Pons Are Important for Bladder Control 370

Dorsolateral Brain Stem Lesions Interrupt Descending Sympathetic Fibers 372

Preganglionic Neurons Are Located in the Lateral Intermediate Zone of the Spinal Cord 374

**Summary 374**



## 16 The Limbic System and Cerebral Circuits for Emotions, Learning, and Memory 377

**Anatomical and Functional Overview of Neural Systems for Emotions, Learning, and Memory 378**

The Limbic Association Cortex Is Located on the Medial Surface of the Frontal, Parietal, and Temporal Lobes 381

The Hippocampal Formation Plays a Role in Memory Consolidation 382

The Amygdala Contains Three Major Functional Divisions 386

Connections Exist Between Components of the Limbic System and the Effector Systems 388

All Major Neurotransmitter Regulatory Systems Have Projections to the Limbic System 389

**Regional Anatomy of Neural Systems for Emotions, Learning, and Memory 392**

The Nucleus Accumbens and Olfactory Tubercle Comprise Part of the Basal Forebrain 393

Basal Forebrain Cholinergic Systems Have Diffuse Limbic and Neocortical Projections 393

The Cingulum Courses Beneath the Cingulate and Parahippocampal Gyri 394

The Three Nuclear Divisions of the Amygdala Are Revealed in Coronal Section 395

The Hippocampal Formation Is Located in the Floor of the Inferior Horn of the Lateral Ventricle 397

A Sagittal Cut Through the Mammillary Bodies Reveals the Fornix and Mammillothalamic Tract 401

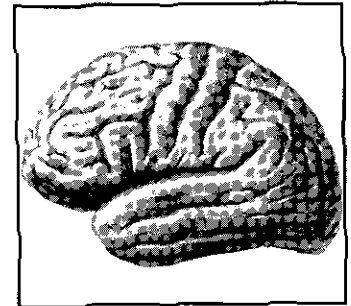
Nuclei in the Brain Stem Link Telencephalic and Diencephalic Limbic Structures With the Autonomic Nervous System and the Spinal Cord 403

**Summary 403**

**V Atlas 407**


# Atlas I

Surface Topography of the Central  
Nervous System 409



# Atlas II

Myelin-Stained Sections Through  
the Central Nervous System 425



Glossary 489

Index 511