

INCLUDES AN ENHANCED INTERACTIVE CD-ROM

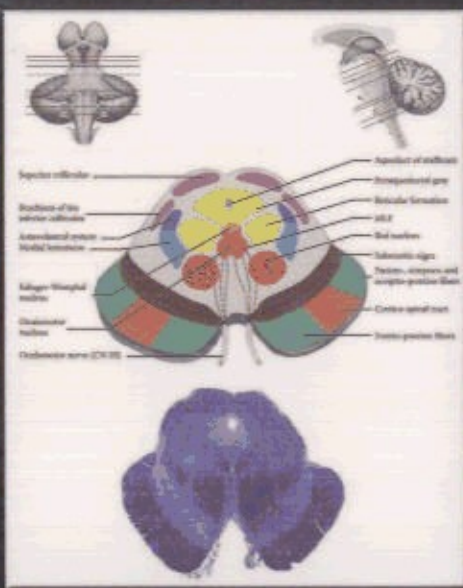
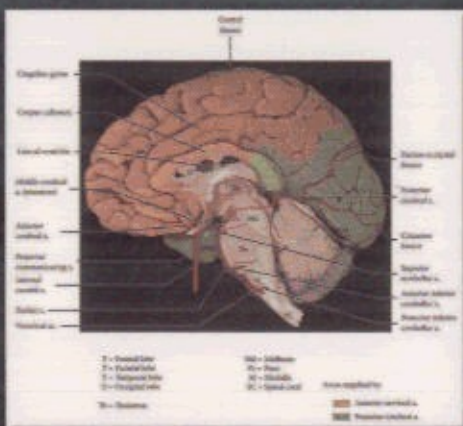
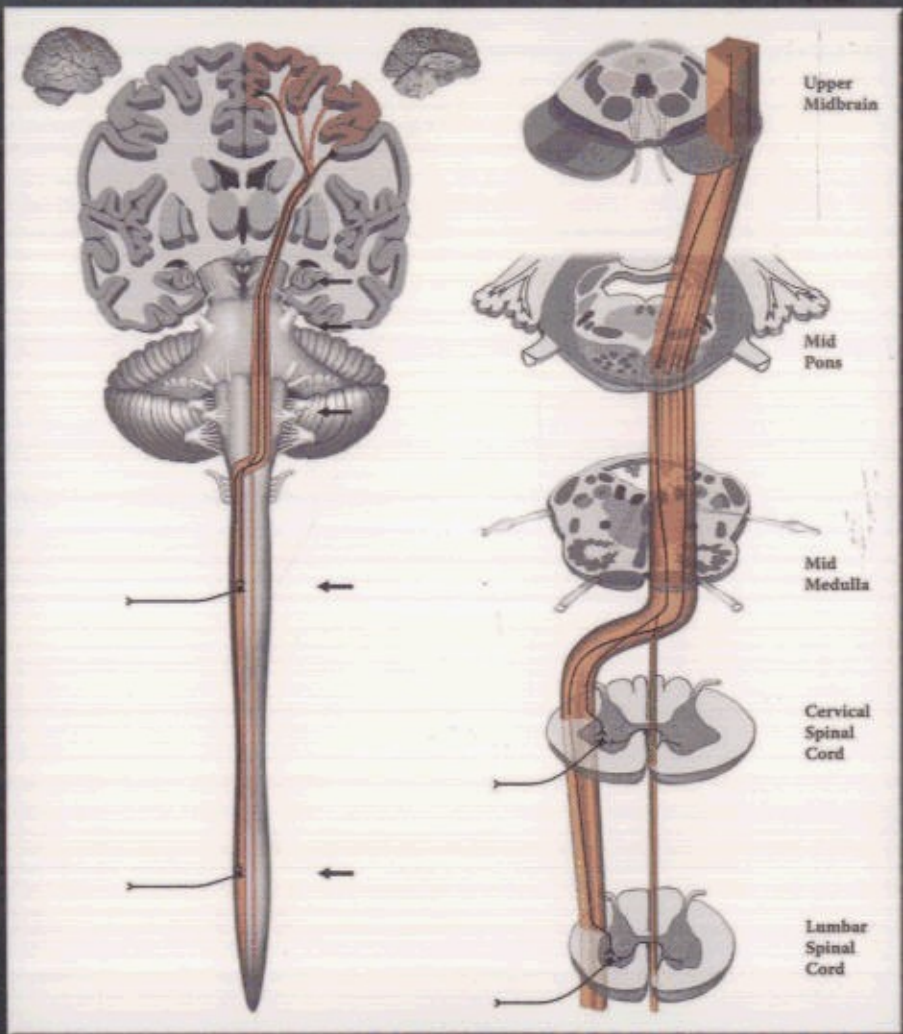


# ATLAS OF FUNCTIONAL NEUROANATOMY

## SECOND EDITION

Fronto-pontine fibers  
Cortico-spinal and cortico-bulbar fibers  
Temporo-parieto-occipito-pontine fibers  
Vestibular n.  
Subro-spinal tract

Oculomotor n.  
Trochlear nerve (CN IV)



WALTER J. HENDELMAN, M.D., C.M.

CRC Taylor & Francis  
Taylor & Francis Group

# CONTENTS

|   |            |
|---|------------|
| List of Illustrations .....                       | xv         |
| User's Guide .....                                | xviii      |
| Foreword .....                                    | xxi        |
| <b>Section A: Orientation .....</b>               | <b>1</b>   |
| Overview .....                                    | 4          |
| Spinal Cord .....                                 | 8          |
| Brainstem .....                                   | 22         |
| Cranial Nerve Nuclei .....                        | 26         |
| Diencephalon .....                                | 36         |
| Thalamus .....                                    | 38         |
| Cerebral Hemispheres .....                        | 40         |
| Cortex .....                                      | 40         |
| Corpus Callosum .....                             | 50         |
| White Matter .....                                | 56         |
| Ventricles .....                                  | 60         |
| Basal Ganglia .....                               | 66         |
| <b>Section B: Funtional Systems .....</b>         | <b>86</b>  |
| Part I: Sensory Systems .....                     | 90         |
| Spinal Cord .....                                 | 90         |
| Dorsal Column .....                               | 92         |
| Anterolateral System .....                        | 94         |
| Trigeminal Pathways .....                         | 96         |
| Audition .....                                    | 100        |
| Vision .....                                      | 108        |
| Part II: Reticular Formation .....                | 114        |
| Part III: Motor Systems .....                     | 120        |
| Spinal Cord .....                                 | 122        |
| Spinal Tract .....                                | 124        |
| Vestibular System .....                           | 138        |
| Medial Longitudinal Fasciculus .....              | 140        |
| Motor Regulatory System .....                     | 142        |
| Cerebellum .....                                  | 146        |
| <b>Section C: Neurological Neuroanatomy .....</b> | <b>156</b> |
| Blood Supply .....                                | 158        |
| Thalamus .....                                    | 170        |
| Brainstem Histology .....                         | 172        |
| The Midbrain .....                                | 176        |
| Pons .....  | 182        |
| Medulla .....                                     | 190        |
| Spinal Cord .....                                 | 198        |
| <b>Section D: The Limbic System .....</b>         | <b>202</b> |
| Limbic Lobe .....                                 | 204        |
| Limbic System .....                               | 208        |
| Hippocampus .....                                 | 210        |
| Amygdala .....                                    | 218        |
| Limbic Crescent .....                             | 222        |

---

|                               |     |
|-------------------------------|-----|
| Limbic Diencephalon .....     | 224 |
| Hypothalamus.....             | 228 |
| Medial Forebrain Bundle ..... | 230 |
| Olfactory System.....         | 232 |
| Basal Forebrain .....         | 234 |
| <br>                          |     |
| Annotated Bibliography.....   | 239 |
| <br>                          |     |
| Glossary .....                | 245 |
| <br>                          |     |
| Index .....                   | 255 |