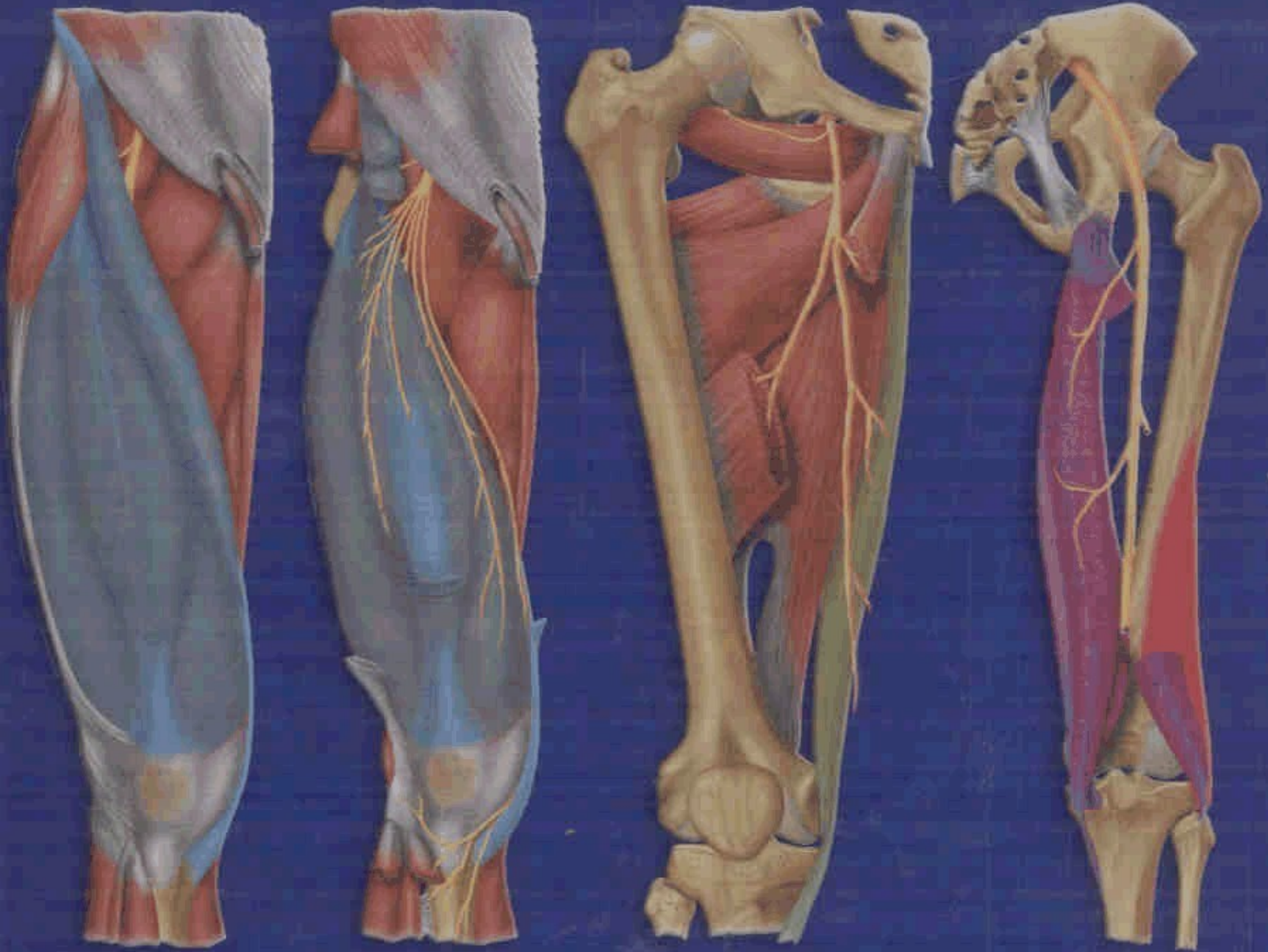


STOLLER'S

ATLAS OF Orthopaedics and Sports Medicine



David W. Stoller



Wolters Kluwer | Lippincott
Williams & Wilkins

Illustrated by
Salvador Beltran

Table of Contents

Preface ix

Acknowledgments xi

Chapter 1 MRI Normal Anatomy: Lower Extremity 1

- The Hip 3
- The Knee 23
- The Ankle and Foot 43

Chapter 2 MRI Normal Anatomy: Upper Extremity 63

- The Shoulder 65
- The Elbow 85
- The Wrist 105

Chapter 3 The Hip 125

Chapter 4 The Knee 261

Chapter 5 The Ankle and Foot 425

Chapter 6 Entrapment Neuropathies of the Lower Extremity 571

Chapter 7 Articular Cartilage 591

Chapter 8 The Shoulder 605

Chapter 9 The Elbow 729

Chapter 10 The Wrist and Hand 811

Chapter 11 The Finger 903

Chapter 12 Entrapment Neuropathies of the Upper Extremity 925

Chapter 13 Marrow Imaging 937

Chapter 14 Bone and Soft-Tissue Tumors 963

Index 999