

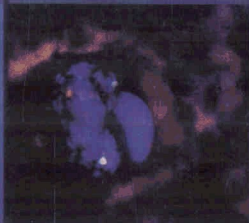
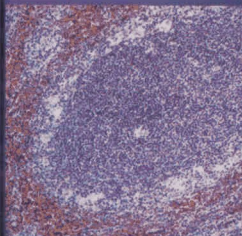

# Flow Cytometry

AND Immunohistochemistry

FOR Hematologic

# Neoplasms

TSIEH SUN



Wolters Kluwer | Lippincott Williams & Wilkins  
Health

# CONTENTS

Preface ix

Acknowledgment xi

CHAPTER 1	General Introduction	1
CHAPTER 2	Principles of Flow Cytometry	4
CHAPTER 3	Principles of Immunohistochemistry	15
CHAPTER 4	Molecular Genetics	24
CHAPTER 5	Classification of Hematologic Neoplasms	34
CHAPTER 6	Clinical Application	45
CASE 1	Chronic Myelogenous Leukemia	52
CASE 2	Myelodysplastic Syndromes	60
CASE 3	Myelodysplastic/Myeloproliferative Diseases	69
CASE 4	Acute Myeloid Leukemia with t(8;21)(q22;q22)	75
CASE 5	Acute Myeloid Leukemia with inv(16)(p13q22) or t(16;16)(p13;q22)	81
CASE 6	Acute Promyelocytic Leukemia with t(15;17)	86
CASE 7	Acute Myeloblastic Leukemia without Maturation (General Introduction of Acute Myeloid Leukemia)	92
CASE 8	Acute Myeloblastic Leukemia with Maturation	101
CASE 9	Acute Myelomonocytic Leukemia	105
CASE 10	Acute Monoblastic and Monocytic Leukemia (M5) and 11q23 (Mixed Lineage Leukemia) Abnormalities	110
CASE 11	Acute Erythroid Leukemia	116
CASE 12	Acute Megakaryoblastic Leukemia	122
CASE 13	Myeloid Sarcoma	129
CASE 14	Precursor B-Lymphoblastic Leukemia/Lymphoma	136
CASE 15	Precursor T-Lymphoblastic Leukemia/Lymphoma	143
CASE 16	Chronic Lymphocytic Leukemia of B-Cell Lineage	152
CASE 17	Chronic Lymphocytic Leukemia of T-Cell Lineage	160

<b>CASE 18</b>	<b>Small Lymphocytic Lymphoma</b>	<b>165</b>
<b>CASE 19</b>	<b>Prolymphocytic Leukemia</b>	<b>172</b>
<b>CASE 20</b>	<b>Lymphoplasmacytic Lymphoma</b>	<b>178</b>
<b>CASE 21</b>	<b>Plasma Cell Myeloma and Plasmacytoma</b>	<b>185</b>
<b>CASE 22</b>	<b>Hairy Cell Leukemia</b>	<b>196</b>
<b>CASE 23</b>	<b>Splenic Marginal Zone Lymphoma</b>	<b>204</b>
<b>CASE 24</b>	<b>Extranodal Marginal Zone B-Cell Lymphoma</b>	<b>210</b>
<b>CASE 25</b>	<b>Nodal Marginal Zone B-Cell Lymphoma</b>	<b>218</b>
<b>CASE 26</b>	<b>Follicular Lymphoma</b>	<b>223</b>
<b>CASE 27</b>	<b>Mantle Cell Lymphoma</b>	<b>232</b>
<b>CASE 28</b>	<b>Diffuse Large B-Cell Lymphoma</b>	<b>241</b>
<b>CASE 29</b>	<b>Mediastinal (Thymic) Large B-Cell Lymphoma</b>	<b>247</b>
<b>CASE 30</b>	<b>Burkitt Lymphoma/Leukemia</b>	<b>253</b>
<b>CASE 31</b>	<b>T-Cell Large Granular Lymphocyte Leukemia</b>	<b>261</b>
<b>CASE 32</b>	<b>Natural Killer Cell Lymphoma</b>	<b>267</b>
<b>CASE 33</b>	<b>Adult T-Cell Leukemia/Lymphoma</b>	<b>277</b>
<b>CASE 34</b>	<b>Hepatosplenic T-Cell Lymphoma</b>	<b>284</b>
<b>CASE 35</b>	<b>Mycosis Fungoides and Sézary Syndrome</b>	<b>289</b>
<b>CASE 36</b>	<b>Peripheral T-Cell Lymphoma, Unspecified</b>	<b>297</b>
<b>CASE 37</b>	<b>Anaplastic Large Cell Lymphoma</b>	<b>304</b>
<b>CASE 38</b>	<b>Hodgkin Lymphoma</b>	<b>312</b>
<b>CASE 39</b>	<b>Thymoma</b>	<b>322</b>