
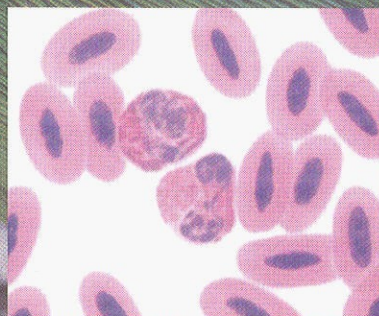


ATLAS OF CLINICAL AVIAN HEMATOLOGY

PHILLIP CLARK, WAYNE BOARDMAN AND SHANE RAIDAL



 WILEY-BLACKWELL

Contents

| | | | |
|---|-----------|---|-----------|
| <i>Dedication</i> | vii | Leukocytes | 40 |
| <i>Authors</i> | viii | Thrombocytes | 49 |
| <i>Foreword</i> | ix | Hematopoiesis | 51 |
| <i>Preface</i> | xi | | |
| <i>Acknowledgements</i> | xiii | 3 Particular hematological characteristics of birds | 53 |
| 1 Collection and handling of blood samples | 1 | Introduction | 53 |
| Introduction | 1 | Anseriformes (ducks, geese and swans) | 54 |
| Taxonomy | 2 | Apodiiformes (swifts and hummingbirds) | 57 |
| Safety aspects | 5 | Caprimulgiiformes (frogmouths, goatsuckers and owlet-nightjars) | 57 |
| Effects of anesthesia on the hematological characteristics of birds | 5 | Charadriiformes (gulls and shorebirds) | 58 |
| Volume of blood | 6 | Ciconiiformes (herons, ibis and storks) | 60 |
| General aspects of collection of blood from birds | 6 | Coliiformes (mousebirds) | 61 |
| Sites for vascular access in birds | 7 | Columbiformes (pigeons and doves) | 62 |
| Anticoagulants | 15 | Coraciiformes (kingfishers, bee-eaters, hornbills, motmots, rollers and todies) | 64 |
| Blood films | 16 | Cuculiformes (cuckoos, roadrunners and turacos) | 66 |
| Post-collection artifacts | 23 | Falconiformes (falcons, hawks and eagles) | 66 |
| Measurement of hematological cells | 27 | Galliformes (grouse, megapodes, curassows, pheasant, partridge, quail and turkey) | 71 |
| 2 General hematological characteristics of birds | 33 | | |
| Introduction | 33 | | |
| Erythrocytes | 33 | | |

| | | | |
|---|----|--|------------|
| Gaviiformes (divers and loons) | 74 | 4 Physiological and pathological influences on the hematological characteristics of birds | 97 |
| Gruiformes (bustards, button quail, coots and cranes) | 74 | Introduction | 97 |
| Opisthocomiformes (hoatzin) | 77 | Physiological effects on the hematological characteristics of birds | 97 |
| Passeriformes (song birds) | 77 | Pathological effects on the hematological characteristics of birds | 100 |
| Pelecaniformes (cormorants, frigate birds, gannets, pelicans and tropicbirds) | 81 | | |
| Phoenicopteriformes (flamingos) | 82 | | |
| Piciformes (toucans and woodpeckers) | 83 | | |
| Podicipediformes (grebes) | 85 | 5 Hemoparasites of birds | 125 |
| Procellariiformes (albatrosses, fulmars, petrels and shearwaters) | 85 | Introduction | 125 |
| Psittaciformes (cockatoos, lories, macaws and parrots) | 86 | Detection of hemoparasites | 127 |
| Sphenisciformes (penguins) | 91 | Morphology of hemoparasites | 129 |
| Strigiformes (barn owls and "typical" owls) | 92 | <i>References</i> | 139 |
| Struthioniformes (cassowaries, emus, kiwis, ostriches and rheas) | 94 | <i>Species list: alphabetically by common name</i> | 163 |
| Tinamiformes (tinamous) | 96 | <i>Species list: by order</i> | 168 |
| Trogoniformes (trogons and quetzals) | 96 | <i>Glossary</i> | 173 |
| | | <i>Index</i> | 177 |