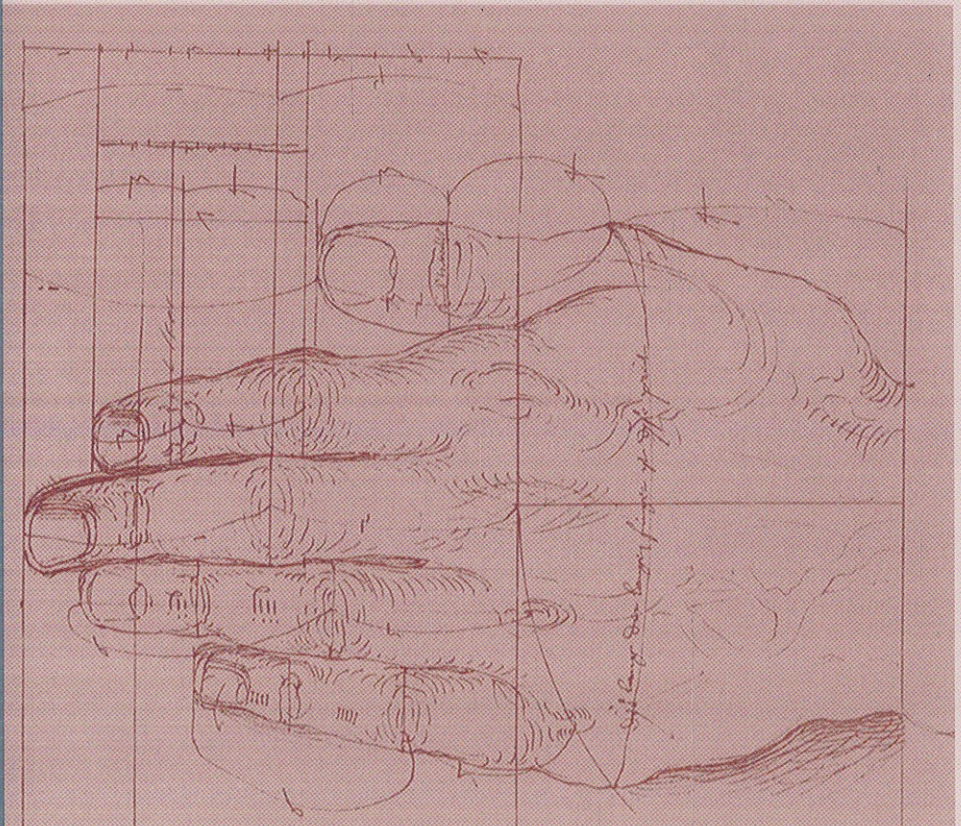


# Sports Injuries of the Elbow and Hand

GUEST EDITOR: **William B. Geissler, MD**

## HAND CLINICS



# Contents

## Preface

xi

William B. Geissler

## The Emerging Role of Elbow Arthroscopy in Chronic Use Injuries and Fracture Care

305

Jennifer W. Hsu, Jason L. Gould, Habimana Fonseca-Sabune, and Michael H. Hausman

Arthroscopy is emerging as an invaluable tool for diagnosing and treating elbow pathology. In addition to the advantages of less scarring, decreased risk of infection, less postoperative pain, and a more thorough visualization of the elbow joint, arthroscopy is particularly well suited to the treatment of athletes trying to minimize rehabilitation and inactivity. Indications for elbow arthroscopy now extend well beyond diagnosis and loose body removal, and include the treatment of impingement, arthritis, contractures, fragment stabilization for osteochondritis dessicans, and treatment of certain fractures. This article reviews the basic principles and techniques of elbow arthroscopy and their application to common sports-related conditions, such as valgus overload syndrome, medial collateral ligament insufficiency, and the various causes of lateral elbow pain. Newer applications of elbow arthroscopy in fracture care are addressed as well.

## Arthroscopic and Open Radial Ulnohumeral Ligament Reconstruction for Posterolateral Rotatory Instability of the Elbow

323

Felix H. Savoie III, Larry D. Field, and Daniel J. Gurley

Arthroscopic repair and/or plication of the radial ulnoligament (RUHL) complex can be as successful as open repair. The diagnosis of posterolateral rotatory instability (PLRI), made by a combination of positive clinical findings and radiologic evidence, can be confirmed by arthroscopic examination. The authors describe four clinical tests for PLRI. Magnetic resonance arthrography is recommended to assist in the preoperative evaluation. In surgical cases, the means to arthroscopically confirm instability are explained. Finally, the authors describe a repair and a ligament plication technique that can be performed by either arthroscopic or open technique with a high rate of success. Arthroscopic repair/plication of the RUHL is thought to effectively stabilize an elbow with PLRI, producing a high degree of patient satisfaction.

## Open and Arthroscopic Management of Lateral Epicondylitis in the Athlete

331

Mark S. Cohen and Anthony A. Romeo

Lateral epicondylitis is the most common condition affecting the adult elbow. It occurs in middleaged individuals and is self-limiting in most cases. Based on clinical, histologic, and imaging data, the tendinous origin of the extensor carpi radialis brevis is the most likely site of pathology. When conservative measures fail, surgical management may be indicated. This can be accomplished by traditional open methods or by arthroscopic release. This article reviews the relevant anatomy of the common extensor tendon origin at the elbow and provides guidelines for surgical management of recalcitrant epicondylitis. Special emphasis is placed on arthroscopic

techniques, which, when required, may allow for a more rapid return of the athlete to sport.

### **Medial Collateral Ligament Reconstruction in the Baseball Pitcher's Elbow**

339

Holger C. Erne, Ioannis C. Zouzas, and Melvin P. Rosenwasser

Pitchers are prone to elbow injuries because of high and repetitive valgus stresses on the elbow. The anterior bundle of the medial ulnar collateral ligament (MCL) of the elbow is the primary restraint and is often attenuated with time, leading to functional incompetence and ultimate failure. Pitchers with a history of medial elbow pain, reduced velocity, and loss of command may have an MCL injury in evolution. Physical examination and imaging can confirm the diagnosis. Treatment begins with rest and activity modification. All medial elbow pain is not MCL injury. Surgery is considered only for talented athletes who wish to return to competitive play and may include elite scholastic and other collegiates and professionals. The technique for MCL reconstruction was first described in 1986. Many variations have been offered since then, which can result in predictable outcomes, allowing many to return to the same level of competitive play.

### **Biceps Tendon Injuries in Athletes**

347

Zinon T. Kokkalis and Dean G. Sotereanos

Although rare, athletes involved in competitive strength training and contact sports may sustain distal tendon biceps injuries. Treatment of complete distal biceps tendon ruptures in athletes is primarily surgical. Early repair, through either one-incision or two-incision techniques with anatomic reinsertion of the ruptured tendon to the bicipital tuberosity, is highly recommended. In this article the etiology and pathophysiology of distal biceps tendon ruptures, current diagnostic modalities, and surgical indications are discussed. Also, treatment options, surgical techniques, outcomes, and potential complications are reviewed.

### **Arthroscopic Management of Scaphoid Fractures in Athletes**

359

William B. Geissler

Fractures of the scaphoid are a common athletic injury. In this article the indications and treatment strategy for arthroscopic management of scaphoid fractures and non-unions in athletes are reviewed. Various arthroscopic assisted and percutaneous techniques for the fixation of fractures of the scaphoid are discussed, including the volar and dorsal percutaneous approaches, and arthroscopic reduction by the Geissler technique. In general, these techniques include a small amount of wrist arthroscopy and a significant amount of fluoroscopy.

### **Carpal Fractures in Athletes Excluding the Scaphoid**

371

Jeffrey Marchessault, Matt Conti, and Mark E. Baratz

A wide range of hand and wrist injuries occur in today's recreational and elite athletes and account for 3% to 9% of all sports injuries. The onus is on the physician to discriminate between injuries that can be managed with an early return to sport, and those injuries that place the athlete at risk of further injury if they are not managed aggressively from the outset. The physician and the athlete must understand the balance between safe, early return to sport, and prompt surgical treatment that prevents late disability.

**Repair of Arthroscopic Triangular Fibrocartilage Complex Tears in Athletes** 389

Periklis A. Papapetropoulos and David S. Ruch

Triangular fibrocartilage complex (TFCC) injuries are a common source of wrist pain in athletes. These injuries constitute a unique orthopedic challenge because of the particular physical demands on these patients. A specialized management approach is often necessary, due to the short recovery time available and the need for high demand performances afterward. Arthroscopic repair of TFCC is becoming the treatment of choice in this group of patients.

**Management of Carpal Instability in Athletes** 395

Joseph F. Slade III and Matthew D. Milewski

Hand and wrist injuries are common in most athletic events and sports. Carpal fractures and ligamentous injuries are common in athletes and require physicians, trainers, and therapists who treat and diagnosis these injuries to have an understanding of the carpal bone anatomy and vascularity along with the potential for progression to instability. Research is still needed to further investigate the optimal treatments of all carpal injuries in athletes along with designing new means to prevent these injuries.

**Operative Fixation of Metacarpal and Phalangeal Fractures in Athletes** 409

William B. Geissler

Metacarpal and phalangeal fractures are common athletic injuries that can significantly affect the athlete's career when they occur during the season and affect the athlete's training when they occur in the off season. This situation is particularly relevant if there are complications or if fixation is not stable enough to permit early range of motion and rehabilitation. This article discusses percutaneous and open reduction techniques of hand fractures as these injuries pertain to athletes. The goal is stable fixation to allow early return to competition and rehabilitation.

**Management of Proximal Interphalangeal Joint Dislocations in Athletes** 423

Randy R. Bindra and Brian J. Foster

Proximal interphalangeal joint dislocations are common athletic injuries. In dislocations and fracture dislocations, the most important treatment principle is congruent joint reduction and maintenance of stability. This article reviews the relevant anatomy, injury characteristics, and treatment options for proximal interphalangeal joint dislocations and fracture dislocations. Treatment methods discussed include closed reduction, percutaneous fixation, and open reduction.

**Acute Ulnar Collateral Ligament Injury in the Athlete** 437

Jeff W. Johnson and Randall W. Culp

The functional thumb is a necessity for successful athletic participation. It not only allows the athlete to manipulate athletic equipment but also allows the precise manipulation of objects in the athlete's hand. Injury to the thumb often negates power grip and finesse of the athletic hand. Injuries can range from fractures, to dislocations, to ligamentous injuries. The relatively unconstrained thumb metacarpophalangeal joint is particularly vulnerable to injury from an abduction moment to its distal segment. Such injuries occur from direct contact and with falls on equipment

such as racquet handles and ski poles. The stability of the athlete's metacarpophalangeal joint must be restored to allow for a productive return to sport.

**Bracing and Rehabilitation for Wrist and Hand Injuries in Collegiate Athletes** **443**

Shannon Singletary and William B. Geissler

Athletic injuries of the hand and wrist are common. The key to management of these injuries is prevention. Certain sports require athletes to participate in positions that pose a higher risk of injury to the fingers and wrists. Once healing of the injured digit and wrist has occurred, rehabilitation of the injury is important. This requires close communication between the therapist and the strength and conditioning coach to allow strengthening exercises but limit traction to the involved injury in order to limit the risk of reinjury. Finally, once the injury has been rehabilitated, protective playing casts and splints are useful to allow the athlete to return early to competition and to decrease the risk of reinjury.

**Index**

**449**